



THE COLLEGE OF  
OPTOMETRISTS

# Stage Two

## Overarching case scenario 22

**AGE AND GENDER** Female Aged 85 years

**ETHNIC BACKGROUND.** Caucasian

**OCCUPATION AND HOBBIES** "Pottering about the house and looking after myself ". Non-driver.

**PRESENTING SYMPTOMS AND HISTORY.** Spectacles are not much help any more as can't see small print. but wears constantly. Had them for at least 5 years. Using large diameter hand-held magnifier (home-help bought from local supermarket but finds it too heavy to hold). Went to eye hospital about 4 years ago and told nothing could be done. Struggling to see subtitles on TV - needs because going deaf - can't sit closer because fire in the way. Sister has glaucoma.

**GENERAL HEALTH AND MEDICATION** Osteoporosis. Takes a calcium tablet and quinine for leg cramps. BP checked by nurse regularly and OK. Slightly deaf (no hearing aid).

**PRESENT Rx, CENTRATION AND ACUITIES** -stuck together with tape and they are now far too big for face. CR39 Round 25 bifocal ocd 58/55

RE: +1.25/+1.00x180 6/36. Near Add +2.50 N14

LE+1.50/+0.50 x 10 6/36. Near Add +2.50 N14

**PD/NCD** 58/55 at 33cms

**VISION**

Distance RE: 3/60. LE 6/60

Near RE: N36. LE N36

**PINHOLE VISION** Could not align

**REFRACTION**

RE:+0.75/+1 .50 x 175 6/36+1

LE:+1.00 /+0.75 x 15. 6/36+1

Add +4.00 RE N14 LE N14

Add +12.00 RE N5. LE N5

**ACCOMMODATION** Not recorded

**BINOCULAR STATUS**

CT without Rx No movement seen on cover/uncover distance or near

**MOTILITY** : Full, no diplopia but lost concentration

**CONVERGENCE** : NPC = 10cms

**PUPIL REACTIONS** direct consensual and near reflexes present, no RAPD

**FUNDUS EXAMINATION** see attached

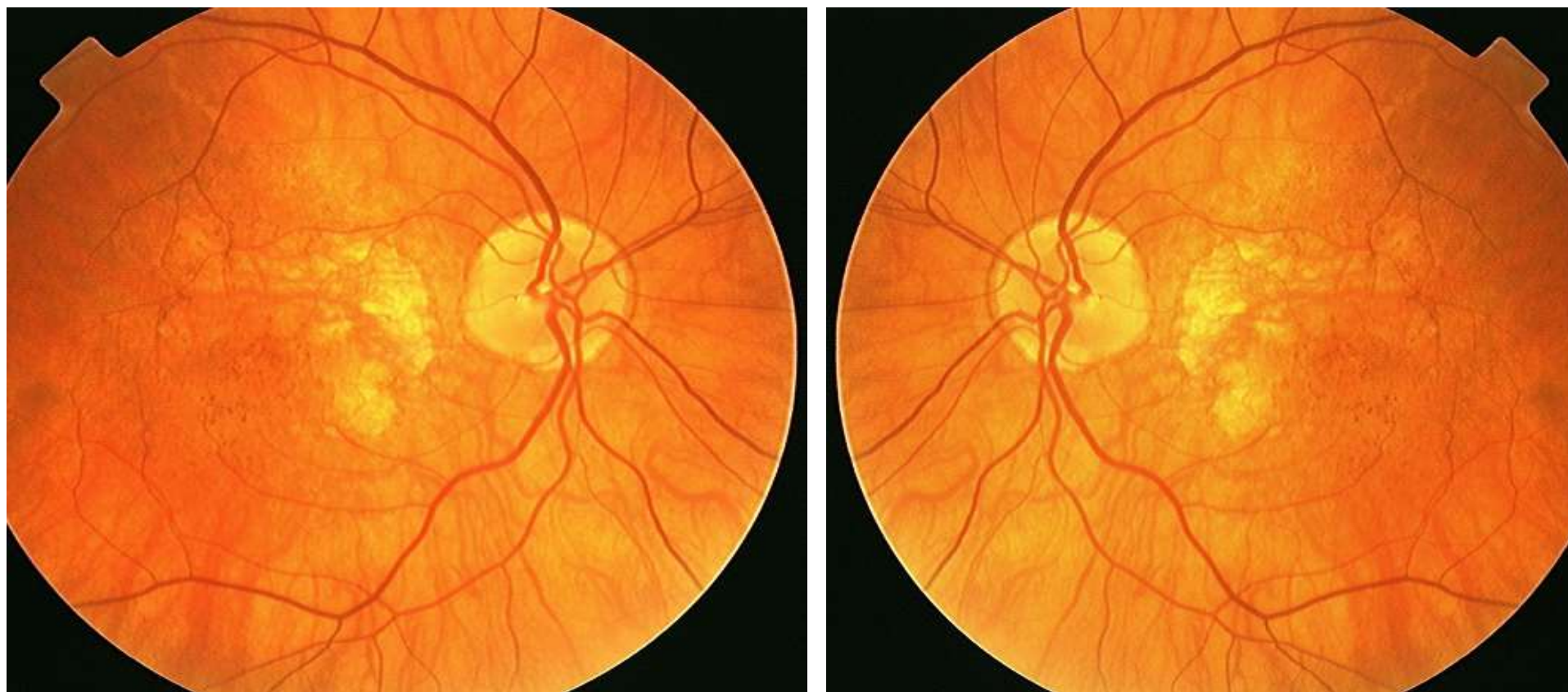
**FIELDS** not recorded

**IOP** RE: 19mmHg LE: 20mmHg Perkins 2.00pm

**EXTERNAL EYE EXAMINATION** see attached

**COLOUR VISION** not done

# Fundus Image



# External Eyes

